

Tilburg University

Vertebroplasty versus conservative treatment in acute osteoporotic vertebral compression fractures (Vertos II)

Klazen, C.A.; Lohle, P.N.; de Vries, J.; Jansen, F.H.; Tielbeek, A.V.; Blonk, M.C.; Venmans, A.; van Rooij, W.J.J.; Schoenmaker, M.C.; Juttmann, J.R.; Lo, T.H.; Verhaar, H.J.J.; van der Graaf, Y.; van Everdingen, K.J.; Muller, A.F.; Elgersma, O.E.H.; Halkema, D.R.; Fransen, H.; Janssens, X.; Buskens, E.; Mali, W.P.Th.M.

Published in:

The Lancet: A Journal of British and Foreign Medicine, Surgery, Obstetrics, Physiology, Pathology, Pharmacology, Public Health and News

Publication date:
2010

Document Version
Publisher's PDF, also known as Version of record

[Link to publication in Tilburg University Research Portal](#)

Citation for published version (APA):

Klazen, C. A., Lohle, P. N., de Vries, J., Jansen, F. H., Tielbeek, A. V., Blonk, M. C., Venmans, A., van Rooij, W. J. J., Schoenmaker, M. C., Juttmann, J. R., Lo, T. H., Verhaar, H. J. J., van der Graaf, Y., van Everdingen, K. J., Muller, A. F., Elgersma, O. E. H., Halkema, D. R., Fransen, H., Janssens, X., ... Mali, W. P. T. M. (2010). Vertebroplasty versus conservative treatment in acute osteoporotic vertebral compression fractures (Vertos II): An open-label randomised trial. *The Lancet: A Journal of British and Foreign Medicine, Surgery, Obstetrics, Physiology, Pathology, Pharmacology, Public Health and News*, 376(9746), 1085-1092.

General rights

Copyright and moral rights for the publications made accessible in the public portal are retained by the authors and/or other copyright owners and it is a condition of accessing publications that users recognise and abide by the legal requirements associated with these rights.

- Users may download and print one copy of any publication from the public portal for the purpose of private study or research.
- You may not further distribute the material or use it for any profit-making activity or commercial gain
- You may freely distribute the URL identifying the publication in the public portal

Take down policy

If you believe that this document breaches copyright please contact us providing details, and we will remove access to the work immediately and investigate your claim.

Vertebroplasty versus conservative treatment in acute osteoporotic vertebral compression fractures (Vertos II): an open-label randomised trial



Caroline A H Klazen, Paul N M Lohle, Jolanda de Vries, Frits H Jansen, Alexander V Tielbeek, Marion C Blonk, Alexander Venmans, Willem Jan J van Rooij, Marinus C Schoemaker, Job R Juttman, Tjoen H Lo, Harald J J Verhaar, Yolanda van der Graaf, Kaspar J van Everdingen, Alex F Muller, Otto E H Elgersma, Dirk R Halkema, Hendrik Fransen, Xavier Janssens, Erik Buskens, Willem P Th M Mali

Summary

Background Percutaneous vertebroplasty is increasingly used for treatment of pain in patients with osteoporotic vertebral compression fractures, but the efficacy, cost-effectiveness, and safety of the procedure remain uncertain. We aimed to clarify whether vertebroplasty has additional value compared with optimum pain treatment in patients with acute vertebral fractures.

Methods Patients were recruited to this open-label prospective randomised trial from the radiology departments of six hospitals in the Netherlands and Belgium. Patients were aged 50 years or older, had vertebral compression fractures on spine radiograph (minimum 15% height loss; level of fracture at Th5 or lower; bone oedema on MRI), with back pain for 6 weeks or less, and a visual analogue scale (VAS) score of 5 or more. Patients were randomly allocated to percutaneous vertebroplasty or conservative treatment by computer-generated randomisation codes with a block size of six. Masking was not possible for participants, physicians, and outcome assessors. The primary outcome was pain relief at 1 month and 1 year as measured by VAS score. Analysis was by intention to treat. This study is registered at ClinicalTrials.gov, number NCT00232466.

Findings Between Oct 1, 2005, and June 30, 2008, we identified 431 patients who were eligible for randomisation. 229 (53%) patients had spontaneous pain relief during assessment, and 202 patients with persistent pain were randomly allocated to treatment (101 vertebroplasty, 101 conservative treatment). Vertebroplasty resulted in greater pain relief than did conservative treatment; difference in mean VAS score between baseline and 1 month was -5.2 (95% CI -5.88 to -4.72) after vertebroplasty and -2.7 (-3.22 to -1.98) after conservative treatment, and between baseline and 1 year was -5.7 (-6.22 to -4.98) after vertebroplasty and -3.7 (-4.35 to -3.05) after conservative treatment. The difference between groups in reduction of mean VAS score from baseline was 2.6 (95% CI 1.74 – 3.37 , $p < 0.0001$) at 1 month and 2.0 (1.13 – 2.80 , $p < 0.0001$) at 1 year. No serious complications or adverse events were reported.

Interpretation In a subgroup of patients with acute osteoporotic vertebral compression fractures and persistent pain, percutaneous vertebroplasty is effective and safe. Pain relief after vertebroplasty is immediate, is sustained for at least a year, and is significantly greater than that achieved with conservative treatment, at an acceptable cost.

Funding ZonMw; COOK Medical.

Introduction

Vertebral compression fractures in osteoporosis are common in the elderly population, with an estimated 1.4 million new fractures occurring every year worldwide.¹ About a third of new fractures come to medical attention, suggesting that most are either asymptomatic or have tolerable symptoms.² Patients with an acute vertebral fracture can present with severe back pain lasting for weeks to months. Until recently, bed rest, analgesia, and cast and physical support were the only treatment options. Vertebroplasty, involving percutaneous injection of bone cement into the fractured vertebral body, was introduced as an alternative option for treatment of pain. Since its introduction, this minimally invasive technique has gained widespread recognition, effectively reducing pain both in the short

and long term.^{3–12} Two randomised studies with a sham control intervention have reported clinical outcomes 1 month and 6 months after percutaneous vertebroplasty in patients with osteoporotic vertebral fractures up to a year old.^{13,14} Results of both studies seem to show that vertebroplasty and sham treatment are equally effective. However, clinical interpretation of these studies is hampered by inclusion of patients with subacute and chronic fractures instead of acute fractures, absence of a control group without intervention, inconsistent use of bone oedema on MRI as an inclusion criterion, and other methodological issues.¹⁵ We aimed to clarify whether percutaneous vertebroplasty has additional value compared with optimum pain treatment in a well defined group of patients with acute vertebral compression fractures.

Published Online
August 10, 2010
DOI:10.1016/S0140-6736(10)60954-3

See Online/Comment
DOI:10.1016/S0140-6736(10)61162-2

Radiology (C A H Klazen MD, P N M Lohle MD, A Venmans MD, Prof W J J van Rooij MD, M C Schoemaker MD), **Medical Psychology** (Prof J de Vries PhD), and **Internal Medicine** (J R Juttman MD), **St Elisabeth Ziekenhuis, Tilburg, Netherlands; Radiology** (F H Jansen MD, A V Tielbeek MD) and **Internal Medicine** (M C Blonk MD), **Catharina-Ziekenhuis, Eindhoven, Netherlands; Radiology** (T H Lo MD, Prof W P Th M Mali MD) and **Geriatric Medicine** (H J J Verhaar MD, C A H Klazen), **University Medical Center Utrecht, Utrecht, Netherlands; Clinical Epidemiology, Julius Centre for Health Sciences and Primary Care, University Medical Centre Utrecht, Utrecht, Netherlands** (Prof Y van der Graaf MD); **Radiology** (K J van Everdingen MD) and **Internal Medicine** (A F Muller MD), **Diakonessenhuis Utrecht, Utrecht, Netherlands; Radiology** (O E H Elgersma MD) and **Internal Medicine** (D R Halkema, MD), **Albert Schweitzer Ziekenhuis, Dordrecht, Netherlands; Radiology** (H Fransen MD), and **Rheumatology** (X Janssens MD), **AZ St Lucas, Gent, Belgium; and Department of Epidemiology, University Medical Centre Groningen, Groningen, Netherlands** (Prof E Buskens MD)

Correspondence to:
Dr Caroline A H Klazen, St Elisabeth Ziekenhuis, Radiology, Hilvarenbeekseweg 60, Tilburg, Netherlands
cahklazen@hotmail.com

Methods

Study design and patients

The methods of this study, including the protocol, patient selection, and clinical outcome measures, have been described in detail elsewhere;¹⁶ in this Article, we mainly report on evolution of pain and cost-effectiveness of vertebroplasty. In short, we undertook an open-label randomised controlled trial in five large teaching hospitals in the Netherlands and one in Belgium. Patients were recruited at the radiology departments of the participating centres. All patients aged 50 years or older who were referred by their general practitioner for spine radiography because of back pain were asked to complete a short questionnaire about presence, severity, and duration of pain by a nurse practitioner. Inclusion criteria were: vertebral compression fracture on spine radiograph (minimum 15% height loss); level of fracture at Th5 or lower; back pain for 6 weeks or less; visual analogue scale (VAS) score of 5 or more; bone oedema of vertebral fracture on MRI; focal tenderness at fracture level, as assessed by an internist on physical examination; and decreased bone density (T scores ≤ -1). Exclusion criteria were: severe cardiopulmonary comorbidity; untreatable coagulopathy; systemic or local spine infection; suspected underlying malignant disease; radicular syndrome; spinal-cord compression syndrome; and contraindication for MRI. Eligible patients were contacted and requested to consider participation in the study. Patients who agreed to participate were referred to an internist who reassessed complaints, took an additional VAS score, and obtained written informed consent. The study protocol was approved by the institutional review board at each participating centre.

See Online for webappendix

Procedures

Patients were randomly allocated to percutaneous vertebroplasty or conservative treatment by an independent central telephone operator using computer-generated randomisation codes with a block size of six. Masking was not possible for participants, physicians, and outcome assessors. Percutaneous vertebroplasty was done on a single or biplane angiography system under fluoroscopic guidance. After local infiltration analgesia, two 11 or 13 gauge bone-biopsy needles were placed transpedicularly in the fractured vertebral body. Polymethylmethacrylate bone cement (Osteo-Firm, COOK Medical, Bloomington, IN, USA) was injected through bone-biopsy needles under continuous fluoroscopic monitoring to identify local cement leakage or migration into the venous system towards the lungs. When necessary, additional analgesia was used at the discretion of the treating physician. In patients who had more than one fracture with bone oedema on MRI, all vertebral bodies were treated in one or more procedures. After the procedure, a CT scan of the treated vertebral bodies was done with 2 mm slices to identify cement leakage outside the vertebral body or other possible local complications.

Patients were clinically assessed at baseline (the day of vertebroplasty or, in patients assigned to conservative treatment, the day of randomisation), and at 1 day, 1 week, 1 month, 3 months, 6 months, and 1 year afterwards. Throughout follow-up, analgesia in both groups was individually tailored in a stepwise manner from non-opiates to weak opiate derivatives and strong opiate derivatives. Pain treatment was categorised according to WHO classification as 0 (no drugs), 1 (non-opiates—eg, paracetamol, non-steroidal anti-inflammatory agents), 2 (weak opiate derivatives), and 3 (strong opiate derivatives).¹⁷ All patients were prescribed bisphosphonates, calcium supplementation, and vitamin D. Complications and adverse events were recorded. To identify new fractures during follow-up, spine radiographs were done at baseline, 1 month, 3 months, and 1 year. Two radiologists independently undertook morphometric measurements.¹⁸ Disagreements were solved by consensus. A new vertebral fracture was defined as a decrease of at least 4 mm in vertical dimension.² Treatment of new vertebral fractures was according to the initial assigned protocol.

The primary outcome was pain relief at 1 month and 1 year, measured with a VAS score ranging from 0 (no pain) to 10 (worst pain ever).¹⁹ We defined clinically significant pain relief as a decrease in VAS score from baseline of 3 points or more. Pain-free days were defined as days with a VAS score of 3 or lower. The secondary outcome was cost-effectiveness at 1 month and 1 year. Medical costs, time without burdensome pain, and quality-adjusted survival time were recorded. Costs were indexed to 2008 (webappendix) and derived from hospital billing systems and costing guidelines issued by the Dutch health insurance board.²⁰ Quality-adjusted life-years (QALYs) were estimated with the EuroQol-5 dimensions (EQ-5D) questionnaire.^{21,22} We assessed uncertainty with respect to the incremental cost-effectiveness ratio using bootstrapping. The tertiary outcome was quality of life measured with the Quality of Life Questionnaire of the European Foundation for Osteoporosis (QUALEFFO),²³ and physical function measured with the Roland Morris Disability (RMD) questionnaire.²⁴ Standard questionnaires including additional questions about pain treatment, hospital stay, outpatient visits, and medical aids were filled in with the help of a nurse practitioner.

Statistical analysis

On the assumption of a 25% difference in significant pain relief and 20% withdrawals from vertebroplasty, 100 patients were needed in each group ($\alpha=0.05$ and $\beta=0.20$). Endpoints were compared by intention-to-treat analysis. We compared proportions of adverse events, drugs, and baseline fractures using χ^2 tests. *p* values are two-sided. Differences in mean VAS scores between baseline and 1 month and 1 year were assessed with the paired *t* test. We used analysis of variance for repeated measures to examine pain relief, quality of life, and physical function over time. Missing data for pain,

EQ-5D, QUALEFFO, and RMD scores were imputed with linear interpolation and last observation carried forward. Imputation of missing data increased the power, but did not affect the results. In concordance with the study protocol, we analysed significant pain relief over time using a Kaplan-Meier survival analysis. We estimated QALYs by calculating the individual area under the curve of the summary score. Imbalances at baseline were adjusted with linear regression analysis. We defined cost-effectiveness as the ratio of difference in costs and difference in QALYs and the difference in pain-free days. SPSS (version 15.0.1) was used for all analyses.

This trial is registered at ClinicalTrials.gov, number NCT00232466.

Role of the funding source

The sponsors of the study had no role in study design, data collection, data analysis, data interpretation, writing of the report, or the decision to submit for publication. The corresponding author had full access to the data and the final responsibility to submit for publication.

Results

Between Oct 1, 2005, and June 30, 2008, 934 patients were screened for eligibility, of whom 202 were randomly allocated to treatment (101 percutaneous vertebroplasty, 101 conservative treatment). Figure 1 shows the trial profile. Patients allocated to vertebroplasty were treated at a mean of 9.4 (SD 8.1) days after randomisation. Table 1 shows baseline characteristics of both groups. Informed consent was withdrawn after randomisation by six patients assigned to conservative treatment and by two patients assigned to vertebroplasty. Since these patients were not attended in any of the study centres, treatment choice was unknown and follow-up could not be obtained. Six patients assigned to vertebroplasty did not receive the procedure because their health deteriorated before treatment (n=3) or they had spontaneous pain relief (n=3). Follow-up information was obtained for five of these patients. Ten patients assigned to conservative treatment with ongoing invalidating pain requested and received vertebroplasty during follow-up. 163 (81%) participants completed 1 year of follow-up.

98 patients underwent vertebroplasty on 134 vertebrae in 103 procedures that took place a mean of 5.6 weeks (SD 2.9 weeks; range 4–92 days) after onset of symptoms. Mean volume of injected cement per vertebral body was 4.1 mL (SD 1.5; range 1–9). In one vertebral body, the second needle could not be placed properly and cement was injected at one side of the vertebra only. In 31 (30%) procedures, patients received additional intravenous analgesia. Two patients required atropine because of pain-induced vasovagal reaction. One patient developed an acute asthma exacerbation during vertebroplasty that led to stopping of the procedure. The procedure was successfully done 1 week later.

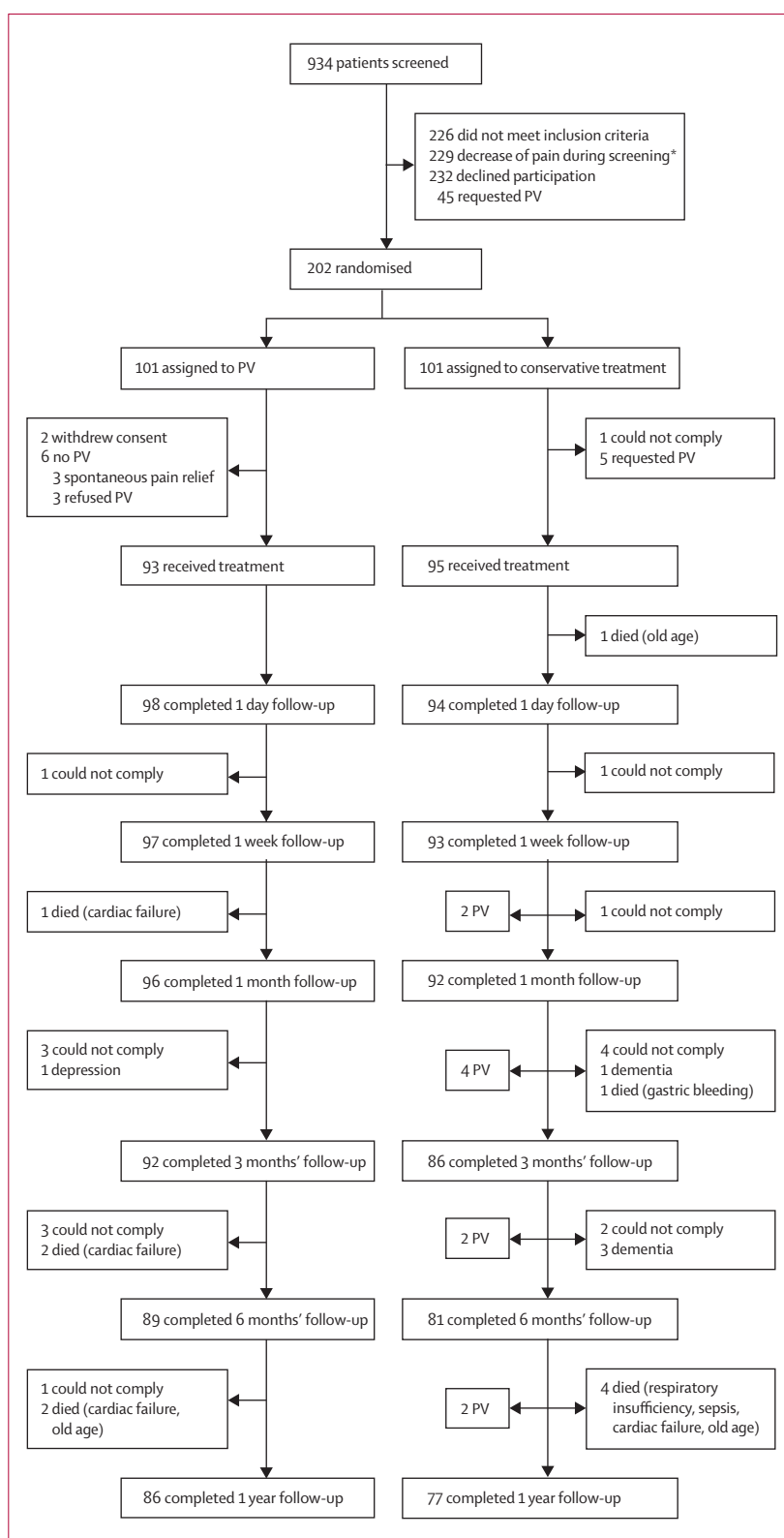


Figure 1: Trial profile

PV=percutaneous vertebroplasty. *Visual analogue scale score lower than 5 at consultation with internist, and thus no longer met inclusion criteria for randomisation.

	Percutaneous vertebroplasty (n=101)	Conservative treatment (n=101)
Age (years)	75.2 (9.8)	75.4 (8.4)
Sex (female)	70 (69%)	70 (69%)
Duration of back pain (days)	29.3 (17.1)	26.8 (16.0)
Initial VAS score	7.8 (1.5)	7.5 (1.6)
Number of VCFs at baseline	2.4 (1.9)*	2.1 (1.5)*
Number and grading of VCFs with bone oedema†		
Mild (10–20%)	57 (42%)	55 (46%)
Moderate (20–40%)	58 (43%)	45 (38%)
Severe (>40%)	21 (15%)	20 (17%)
Wedge	90 (66%)	97 (81%)
Biconcave	46 (34%)	23 (19%)
Crush	0	0
Initial pain treatment		
None	5 (5%)	7 (7%)
Non-opiate drugs	40 (40%)	43 (43%)
Weak opiate derivatives	31 (31%)	22 (22%)
Strong opiate derivatives	19 (19%)	20 (20%)
Vertebral level with bone oedema		
Th5–Th10	19 (14%)	32 (25%)
Th11–L2	91 (65%)	66 (52%)
L3–L5	29 (21%)	28 (22%)
Use of osteoporosis drugs	24 (24%)	26 (26%)
Bone density T score	-3.0 (1.17)	-3.0 (1.05)
EQ-5D score	0.27 (0.03)	0.38 (0.03)
QUALEFFO score	58.7 (13.5)	54.7 (14.4)
RMD score	18.6 (3.6)	17.2 (4.2)

Data are mean (SD) or number (%). VAS=visual analogue scale. VCF=vertebral compression fracture. EQ-5D=EuroQol-5 dimensions. QUALEFFO=Quality of Life Questionnaire of the European Foundation for Osteoporosis. *Range 1–5. †Percentages are proportion of total number of VCFs (136 in percutaneous vertebroplasty group, 120 in conservative treatment group).

Table 1: Baseline characteristics

CT scanning of the 134 treated vertebral bodies showed cement leakage in 97 (72%). Most leakages were discal or into segmental veins; none were into the spinal canal. All patients remained asymptomatic. Fluoroscopy showed cement migration into the venous system towards the lungs in one patient (1%). This patient also remained asymptomatic and a follow-up chest CT after 1 year showed no perifocal inflammatory pulmonary changes.

After a mean follow-up of 11.4 months (median 12.0, range 1–24), 18 new fractures were reported in 15 of 91 patients treated with vertebroplasty and 30 new fractures in 21 of 85 conservatively treated patients. This difference was not significant ($p=0.44$). 12 patients refused follow-up radiographs.

Baseline VAS scores were similar in both groups (table 1). Figure 2 shows reduction in VAS score during follow-up in both groups. Decrease in VAS score after vertebroplasty was significantly higher than with conservative treatment at all timepoints ($F=127.5$; $p<0.001$; power 1.0). The improved pain relief after

vertebroplasty was apparent from 1 day after the procedure (mean VAS score 3.7 [SD 2.4] vs 6.7 [2.1]; $p<0.0001$) and remained significant at 1 week (3.5 [2.5] vs 5.6 [2.5]; $p<0.0001$), 1 month (2.5 [2.5] vs 4.9 [2.6]; $p<0.0001$), 3 months (2.5 [2.7] vs 3.9 [2.8]; $p=0.025$), 6 months (2.3 [2.7] vs 3.9 [2.9]; $p=0.014$), and 1 year (2.2 [2.7] vs 3.8 [2.8]; $p=0.014$).

After vertebroplasty, the difference in mean VAS score between baseline and 1 month was -5.2 (95% CI -5.88 to -4.72), and between baseline and 1 year was -5.7 (-6.22 to -4.98). After conservative treatment, the difference in mean VAS score from baseline was -2.7 (-3.22 to -1.98) at 1 month and -3.7 (-4.35 to -3.05) at 1 year. The difference between groups in reduction of mean VAS score from baseline was 2.6 (1.74 to 3.37, $p<0.0001$) at 1 month, and 2.0 (1.13 to 2.80, $p<0.0001$) at 1 year. Survival analysis showed that significant pain relief ($\chi^2=55.6$, $p<0.0001$) was achieved earlier and in more patients after vertebroplasty (29.7 days until significant pain relief, 95% CI 11.45–47.97) than with conservative treatment (115.6 days, 95% CI 85.87–145.40; figure 3).

At baseline, the class of drugs used for pain relief was similar in both groups. After vertebroplasty, use of drugs was significantly reduced compared with conservative treatment at 1 day ($p<0.0001$), 1 week ($p=0.001$), and 1 month ($p=0.033$). This difference was not significant at later stages of follow-up. At baseline, a significantly lower EQ-5D score was recorded in the vertebroplasty group than in the conservative treatment group (table 1). This difference had to have been caused by chance. After adjustment for baseline use with regression analysis, the difference in QALYs favouring the vertebroplasty group was 0.010 (95% CI 0.014–0.006) at 1 month and 0.108 (0.177–0.040) at 1 year. Both QUALEFFO and RMD scores at baseline were significantly worse for the vertebroplasty group than for the conservative treatment group (table 1). Improvement with time was significantly greater and quicker after vertebroplasty than with conservative treatment, for both QUALEFFO ($p<0.0001$) and RMD ($p<0.0001$) (figure 2).

The difference between treatments in mean total medical costs per patient was €2474 at 1 month and €2450 at 1 year, in favour of conservative treatment (table 2). The higher costs for vertebroplasty compared with conservative treatment at both intervals were roughly equivalent to the cost of the procedure (€2463). During the first year after vertebroplasty, an average 120.3 (95% CI 163.2–77.4) pain-free days were gained. The cost of one pain-free day gained was €20. The adjusted trial-based incremental cost-effectiveness ratio for vertebroplasty, as compared with conservative treatment, was €22685 per QALY gained. Incremental costs and effects were adjusted for each bootstrap sample and the adjusted estimates were displayed in a cost-effectiveness plane (figure 4). These results were further processed to yield a cost-effectiveness acceptability

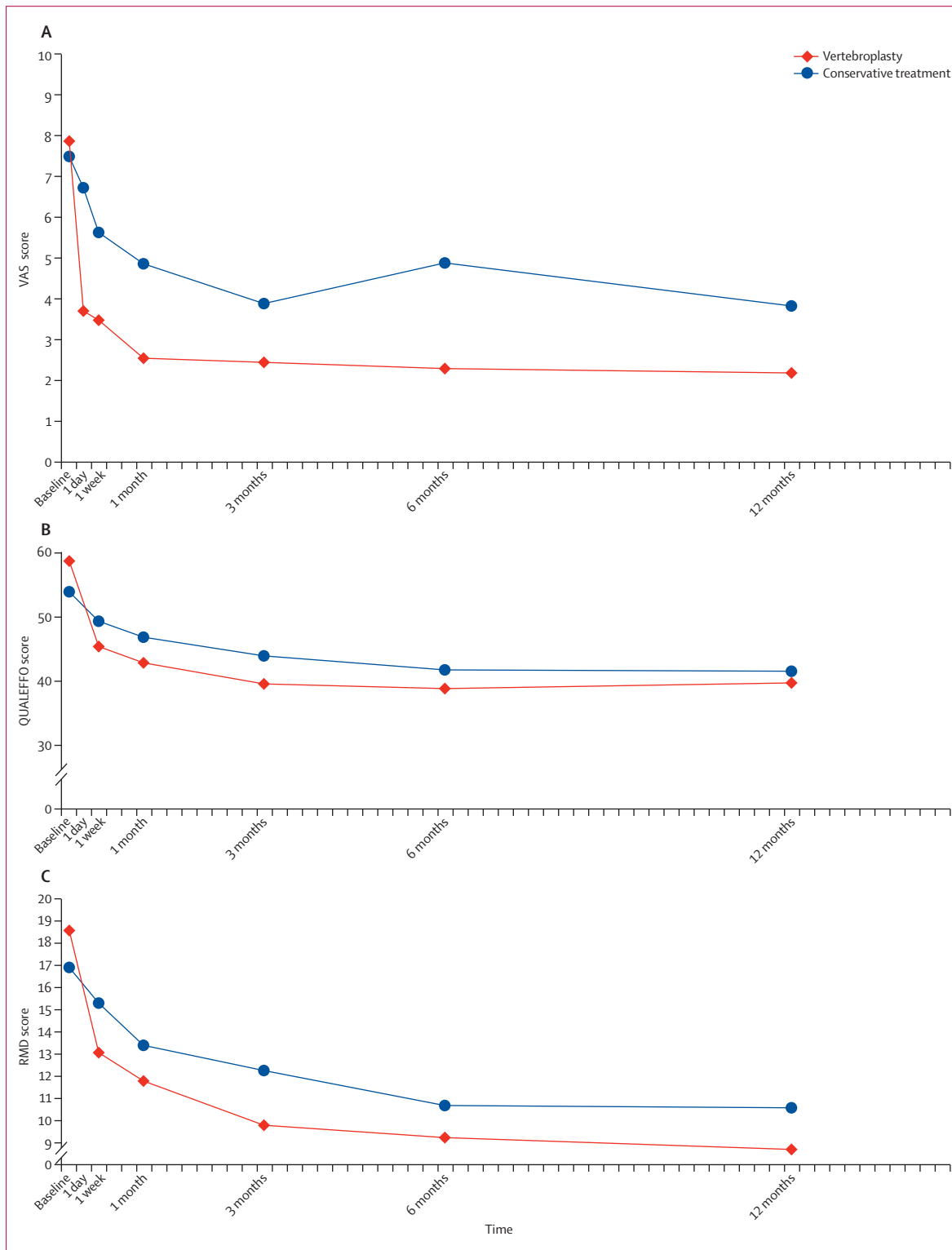


Figure 2: Analysis of variance models for VAS (A), QUALEFFO (B), and RMD scores (C) in vertebroplasty and conservative treatment groups during follow-up VAS=visual analogue scale. QUALEFFO=Quality of Life Questionnaire of the European Foundation for Osteoporosis. RMD=Roland Morris Disability.

curve (figure 4). The curve shows that if society were willing to spend €30 000 or more per QALY gained, vertebroplasty is an acceptable treatment strategy, with more than 70% certainty.

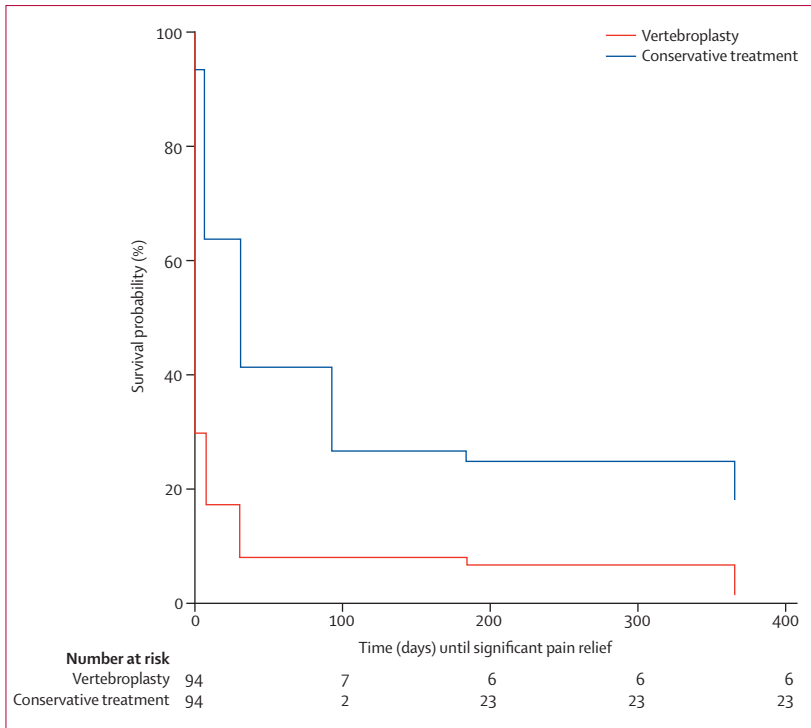


Figure 3: Kaplan-Meier survival curves for significant pain relief in vertebroplasty and conservative treatment groups

	Percutaneous vertebroplasty (n=94)	Conservative treatment (n=93)	p value
Drugs, 1 month	€24.36 (33.61)	€43.51 (50.93)	0.003
Drugs, 1 year	€204.88 (368.47)	€280.47 (352.89)	0.15
Family doctor, 1 month	€23.40 (49.16)	€14.13 (35.70)	0.14
Family doctor, 1 year	€970.30 (1167.49)	€900.11 (1386.70)	0.70
Medical specialist, 1 month	€46.08 (96.56)	€68.87 (169.53)	0.25
Medical specialist, 1 year	€2263.82 (3220.02)	€2138.99 (3558.86)	0.80
Physiotherapist, 1 month	€47.77 (71.71)	€16.68 (49.18)	0.001
Physiotherapist, 1 year	€694.72 (1249.80)	€640.69 (1331.45)	0.77
Hospital admission, 1 year	€2270.62 (9084.55)	€2006.44 (10 081.68)	0.85
PV (including MRI spine, CT spine, day care)*	€2339.60 (542.34)	€233.43 (725.43)	<0.0001
Total costs 1 month	€2611.89 (148.07)	€383.78 (745.66)	<0.0001
Total costs 1 year	€9182.78 (10 779.20)	€6327.45 (11 872.79)	0.087

Data are mean (SD). All patients assigned to percutaneous vertebroplasty (PV; who received the procedure or not) for whom information about costs were available were included in this analysis. *PV costs appear in both columns because several patients assigned to conservative treatment received PV.

Table 2: Direct medical costs

One patient had urinary tract infection after vertebroplasty, and one patient had an asymptomatic cement deposition in a segmental pulmonary artery. 11 patients died of unrelated causes during follow-up: five in the vertebroplasty group and six in the conservative treatment group (figure 1). One patient in the conservative treatment group who died from gastrointestinal bleeding used morphine as their only pain drug.

Discussion

Our results show that in patients with acute osteoporotic vertebral fractures who have persistent severe pain, vertebroplasty done at a mean 5.6 weeks after onset of symptoms resulted in quicker and greater pain relief than did conservative treatment. Notably, in more than half of the patients who initially qualified for the study, pain spontaneously decreased to bearable levels, with a VAS score lower than 5 thereby precluding inclusion. After vertebroplasty, patients had significant pain relief and used a lower class of drugs than did those receiving conservative treatment, or no drugs at all. Pain relief was sustained throughout follow-up. With conservative treatment, pain relief was slower and less than with vertebroplasty, and pain treatment required tended to increase during the first month. Selection of optimum pain treatment and the psychological effect of care and daily attention accounted for the decrease in VAS score in the conservative treatment group during the first week. The Kaplan-Meier survival curve confirmed that significant pain relief was achieved earlier after vertebroplasty than with conservative treatment.

In all patients in both groups, use of analgesic drugs was individually tailored and corrections in dose and class of drugs were made on a day-to-day basis. This strategy implies that the improved pain relief after vertebroplasty compared with conservative treatment is due to the procedure itself, and not to differences in drugs used. The increased pain relief after vertebroplasty remained significant throughout a year of follow-up. This finding is remarkable, since fracture healing in the control group should be completed within several months. However, some patients in the control group developed chronic back pain, possibly because of non-healing of the fracture. Future research could be aimed at identification of these patients. With vertebroplasty, no serious complications occurred. This finding is in line with other studies.^{3,12} Minor cement leakage was frequently noted on CT scan, but leakage was asymptomatic in all cases. During follow-up, the incidence of new fractures after vertebroplasty and after conservative treatment was similar. This finding is in concordance with results of some other studies.^{3,25}

Incremental costs of vertebroplasty roughly equalled procedural costs, but because of substantial interindividual variability with time, especially in the control group, the difference was no longer significant at 1 year. We did not include costs of care by family or professionals at home in our analysis. Since these resources are particularly used in case of continued pain and loss of function they will probably play a more important part in the conservative treatment group. Data for costs and cost-effectiveness are only valid in the Netherlands and might differ for other countries. The resulting incremental cost-effectiveness suggests that vertebroplasty seemed warranted for the patients with vertebral fractures treated at a mean 5.6 weeks after start of symptoms.

Our study as the first open-label randomised controlled trial with mid-term follow-up to compare vertebroplasty with conservative treatment in patients with acute osteoporotic vertebral fracture. Results of a systematic literature review suggested that vertebroplasty effectively relieved pain;¹² however, the included prospective and retrospective follow-up studies did not include control groups for comparison. Improvements in VAS scores that have been reported previously were in concordance with our results. In the VERTOS I study, a small group of patients with subacute vertebral compression fractures who were randomly allocated to vertebroplasty had immediate pain relief and improved mobility during short-term follow-up.²⁶ The results were similar to ours, but the study was stopped early because of many crossovers. In our study, only 10% of patients assigned to conservative treatment crossed over to vertebroplasty.

Two randomised studies reported clinical outcomes after vertebroplasty compared with a sham procedure in patients with osteoporotic vertebral compression fractures.^{13,14} Improvements in pain and pain-related disability were similar in both groups. The sham-controlled studies differed in two important ways from our study. First, we focused on acute fractures, whereas the sham-controlled studies included subacute fractures up to a year old. Second, by contrast with our study, bone oedema on MRI was not a consistent inclusion criterion. These differences might account for the small mean gain in VAS score in the sham-controlled studies compared with both our study and the findings of the 2008 meta-analysis.¹² Apparently, vertebroplasty at a mean 5·6 weeks after onset of symptoms is more effective for pain relief than is treatment up to a year after onset. Finally, the sham-controlled studies did not have a control group without intervention, and the best treatment option remains unclear for the clinician. Our study compared vertebroplasty with the reference treatment and thus provides the clinician with directly applicable information about how to best treat the patient.

The FREE study²⁵ compared kyphoplasty with non-surgical care in 300 patients with acute vertebral compression fractures. Instead of direct cement injection into the vertebral body, as in vertebroplasty, kyphoplasty involves use of an inflatable bone tamp that forms a space in the vertebral body into which cement can be injected. This method is regarded to be in competition with percutaneous vertebroplasty. The design of the FREE study was similar to that of our study, with kyphoplasty used instead of vertebroplasty. Kyphoplasty had a similar favourable effect on pain relief as did vertebroplasty in our study, with rapid and sustained improvement. Also, pain relief in conservatively treated patients was in the same range. An advantage of vertebroplasty is that the procedure can be done on an outpatient basis with local analgesia, whereas kyphoplasty requires general anaesthesia and hospital admission.²⁷ Additionally, kyphoplasty can generate procedural costs that are up to 20 times higher than those of vertebroplasty.²⁸

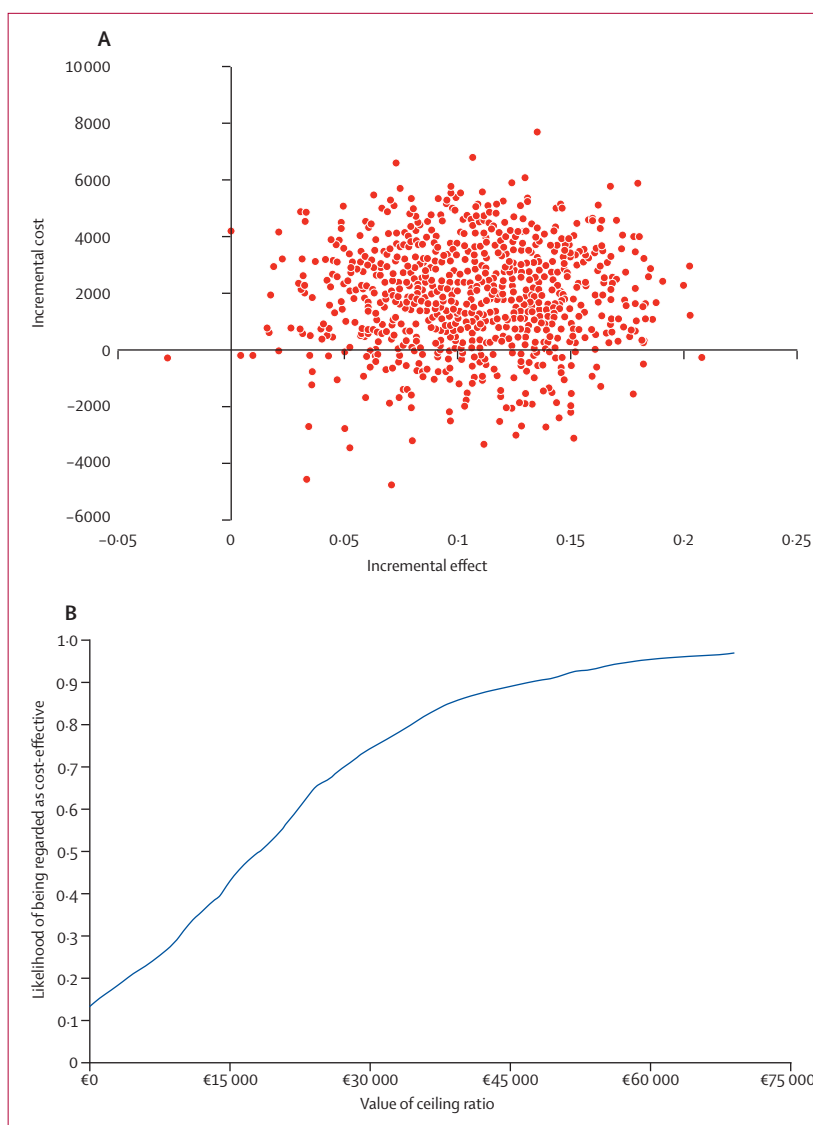


Figure 4: Cost-effectiveness of vertebroplasty compared with conservative treatment
(A) Scatterplot of adjusted point estimates of incremental cost-effectiveness ratios. (B) Adjusted cost-effectiveness acceptability curve.

The main drawback of our study was that treatment could not be masked. Knowledge of the treatment assignment might have affected patient responses to questions or radiologist assessments. Time needed for planning of vertebroplasty resulted in mean delay of 9 days until start of treatment compared with conservative treatment. We believe that this small difference in natural course was unlikely to have affected outcomes at 1 month and 1 year. In conclusion, in a selected subgroup of patients with acute osteoporotic vertebral fractures and persistent pain, vertebroplasty is effective and safe. Pain relief after the procedure is immediate, sustained for 1 year, and is significantly better than that achieved with conservative treatment and at acceptable costs, on the assumption of a societal willingness to pay €30 000 per QALY gained.

Contributors

THL, FHJ, AVT, MCB, MCS, AV, JRJ, KJVE, AFM, HF, XJ, DRH, and OEE contributed to study design, literature search, and data collection. YVDG contributed to study design and data analysis. JDV contributed to data analysis, data interpretation, and writing. EB contributed to study design, data interpretation, data analysis, writing, and figures. WJJVR contributed to data interpretation and writing. WPM, HJV, PNML, and CAHK contributed to study design, data collection, literature search, data analysis, data interpretation, and writing.

Conflicts of interest

We declare that we have no conflicts of interest.

Acknowledgments

This study was sponsored by ZonMw (Dutch organisation for health care research and innovation of care), project number 945-06-351 and an unrestricted grant from COOK Medical (Bloomington, IN, USA).

References

- Johnell O, Kanis JA. An estimate of the worldwide prevalence and disability associated with osteoporotic fractures. *Osteoporos Int* 2006; **17**: 1726–33.
- Black DM, Cummings SR, Karpf DB, et al, for the Fracture Intervention Trial Research Group. Randomised trial of effect of alendronate on risk of fracture in women with existing vertebral fractures. *Lancet* 1996; **348**: 1535–41.
- Hulme PA, Krebs J, Ferguson SJ, Berlemann U. Vertebroplasty and kyphoplasty: a systematic review of 69 clinical studies. *Spine* 2006; **31**: 1983–2001.
- Zoarski GH, Snow P, Olan WJ, et al. Percutaneous vertebroplasty for osteoporotic compression fractures: quantitative prospective evaluation of long-term outcomes. *J Vasc Interv Radiol* 2002; **13**: 139–48.
- McGraw JK, Lippert JA, Minkus KD, Rami PM, Davis TM, Budzik RF. Prospective evaluation of pain relief in 100 patients undergoing percutaneous vertebroplasty: results and follow-up. *J Vasc Interv Radiol* 2002; **13**: 883–86.
- Legroux-Gerot I, Lormeau C, Boutry N, Cotten A, Duquesnoy B, Cortet B. Long-term follow-up of vertebral osteoporotic fractures treated by percutaneous vertebroplasty. *Clin Rheumatol* 2004; **23**: 310–17.
- Voormolen MH, Lohle PN, Lampmann LE, et al. Prospective clinical follow-up after percutaneous vertebroplasty in patients with painful osteoporotic vertebral compression fractures. *J Vasc Interv Radiol* 2006; **17**: 1313–20.
- Anselmetti GC, Corrao G, Monica PD, et al. Pain relief following percutaneous vertebroplasty: results of a series of 283 consecutive patients treated in a single institution. *Cardiovasc Intervent Radiol* 2007; **30**: 441–47.
- Evans AJ, Jensen ME, Kip KE, et al. Vertebral compression fractures: pain reduction and improvement in functional mobility after percutaneous polymethylmethacrylate vertebroplasty retrospective report of 245 cases. *Radiology* 2003; **226**: 366–72.
- Alvarez L, Alcaraz M, Perez-Higueras A, et al. Percutaneous vertebroplasty: functional improvement in patients with osteoporotic compression fractures. *Spine* 2006; **31**: 1113–18.
- Perez-Higueras A, Alvarez L, Rossi RE, Quinones D, Al-Assir I. Percutaneous vertebroplasty: long-term clinical and radiological outcome. *Neuroradiology* 2002; **44**: 950–54.
- Eck JC, Nachtigall D, Humphreys SC, Hodges SD. Comparison of vertebroplasty and balloon kyphoplasty for treatment of vertebral compression fractures: a meta-analysis of the literature. *Spine J* 2008; **8**: 488–97.
- Kallmes DF, Comstock BA, Heagerty PJ, et al. A randomized trial of vertebroplasty for osteoporotic spinal fractures. *N Engl J Med* 2009; **361**: 569–79.
- Buchbinder R, Osborne RH, Ebeling PR, et al. A randomized trial of vertebroplasty for painful osteoporotic vertebral fractures. *N Engl J Med* 2009; **361**: 557–68.
- Clark W, Lyon S, Burnes J, et al. Trials of vertebroplasty for vertebral fractures. *N Engl J Med* 2009; **361**: 2097–100.
- Klazen CA, Verhaar HJ, Lampmann LE, et al. VERTOS II: percutaneous vertebroplasty versus conservative therapy in patients with painful osteoporotic vertebral compression fractures; rationale, objectives and design of a multicenter randomized controlled trial. *Trials* 2007; **8**: 33.
- McHugh GA, Luker KA, Campbell M, Kay PR, Silman AJ. A longitudinal study exploring pain control, treatment and service provision for individuals with end-stage lower limb osteoarthritis. *Rheumatology (Oxford)* 2007; **46**: 631–37.
- Genant HK, Wu CY, van KC, Nevitt MC. Vertebral fracture assessment using a semiquantitative technique. *J Bone Miner Res* 1993; **8**: 1137–48.
- Huskisson EC. Measurement of pain. *Lancet* 1974; **2**: 1127–31.
- Oostenbrink JB, Bouwmans CAM, Koopmanschap MA, Rutten FFH. Dutch guidelines for cost evaluation in health care. Dutch Health Insurance Board. 2004. http://www.cvz.nl/binaries/live/CVZ_Internet/hst_content/nl/documenten/rubriek+zorgpakket/cfh/handleiding+kostenonderzoek.pdf (accessed July 22, 2010).
- Dolan P. Modeling valuations for EuroQol health states. *Med Care* 1997; **35**: 1095–108.
- Lamers LM, Stalmeier PF, McDonnell J, Krabbe PF, van Busschbach JJ. Measuring the quality of life in economic evaluations: the Dutch EQ-5D tariff. *Ned Tijdschr Geneesk* 2005; **149**: 1574–78 (in Dutch).
- Lips P, Cooper C, Agnusdei D, et al. Quality of life in patients with vertebral fractures: validation of the Quality of Life Questionnaire of the European Foundation for Osteoporosis (QUALEFFO). *Osteoporos Int* 1999; **10**: 150–60.
- Roland M, Morris R. A study of the natural history of low-back pain. Part II: development of guidelines for trials of treatment in primary care. *Spine* 1983; **8**: 145–50.
- Wardlaw D, Cummings SR, Van Meirhaeghe J, et al. Efficacy and safety of balloon kyphoplasty compared with non-surgical care for vertebral compression fracture (FREE): a randomised controlled trial. *Lancet* 2009; **373**: 1016–24.
- Voormolen MH, Mali WP, Lohle PN, et al. Percutaneous vertebroplasty compared with optimal pain medication treatment: short-term clinical outcome of patients with subacute or chronic painful osteoporotic vertebral compression fractures. The VERTOS study. *AJNR Am J Neuroradiol* 2007; **28**: 555–60.
- Liu JT, Liao WJ, Tan WC, et al. Balloon kyphoplasty versus vertebroplasty for treatment of osteoporotic vertebral compression fracture: a prospective, comparative, and randomized clinical study. *Osteoporos Int* 2010; **21**: 359–64.
- Mathis JM, Ortiz AO, Zoarski GH. Vertebroplasty versus kyphoplasty: a comparison and contrast. *AJNR Am J Neuroradiol* 2004; **25**: 840–45.